

Effect of Interferon-gamma Treatment on Interstitial Pneumonia in a Patient with Severe Combined Immunodeficiency

Kyung Hyo Kim, Hye Young Kang and Dong Soo Kim

In severe combined immunodeficiency disease, both T and B cell functions are diminished or absent and affected usually succumb to overwhelming infection within the first year of life.

We are reporting a case with severe combined immunodeficiency, Swiss type who suffered from interstitial pneumonia which cleared by treatment with recombinant human interferon gamma.

In this case, we don't know the exact mechanism which caused the clearing of the interstitial pneumonia. However, we can speculate that antiviral action and activated macrophages or monocytes, through the recombinant human interferon gamma, might exert its effect on interstitial pneumonia. Though we should extend its application to more cases of SCID with interstitial pneumonia, this report may suggest a new application for interferon-gamma as a potential corrective and therapeutic agent for interstitial pneumonia in congenital immunodeficiency diseases.

Key Words: SCID, interferon-gamma, interstitial pneumonia

In severe combined immunodeficiency disease, both T and B cell functions are diminished or absent, resulting in early susceptibility to infection by virtually all types of microorganisms (Ammann, 1991).

The disease is inherited in two forms; an X-linked recessive form and an autosomal recessive form. It has been postulated that the defect may reside in the failure of differentiation of stem cells into T cells and B cells or the thymus and bursa equivalent to develop normally. Others argue for an intrinsic defect within the thymus. The causes of a small proportion of cases of autosomally inherited SCID have been defined and have included deficiencies of the enzymes adenine deaminase and purine nucleoside phosphorylase (Hirschhorn, 1983) and of a DNA

binding protein required for the expression of histocompatibility genes (Reith *et al.* 1988). Affected persons usually succumb to overwhelming infection within the first year of life and are particularly susceptible to *Candida*, Cytomegalovirus, and *Pneumocystis carinii* infection.

Since its discovery in 1965 as a new antiviral protein (Wheelock, 1965), much has been learned about the molecule termed "immune" (Falcoff, 1972) or type II interferon which is now known as interferon gamma. This cytokine is secreted by T lymphocytes and natural killer lymphocytes (NK cell) (Kasahara *et al.* 1983; Hardy *et al.* 1989), and modulates the function of a wide variety of cell types, particularly those involved in the immune response (Ijzermans *et al.* 1990).

The immunomodulatory effects of IFN-gamma are the enhancement of class II MHC and Fc receptor expression on circulating mononuclear cells (Amaldi *et al.* 1989), augmentation of natural killer cell function (Thompson *et al.* 1987), and activation of monocyte-macrophages for antimicrobial effect (Murray *et al.* 1988). The availability of recombinant IFN-gamma (Pesta *et al.* 1987) has opened

Received July 24, 1991

Accepted November 18, 1991

Department of Pediatrics, Yonsei University College of Medicine, Seoul, Korea

Address reprint requests to Dr. D S Kim, Department of Pediatrics, Yonsei University College of Medicine, CPO Box 8044 Seoul, Korea, 120-752

new avenues for investigating the therapeutic potential of IFN-gamma. It has been administered to patients for treatment of cancer (Jaffe *et al.* 1986) and infection (Cooper *et al.* 1989; Badaro *et al.* 1990) and/or immunodeficiency disorders especially chronic granulomatous disease (Gallin *et al.* 1990) and Job syndrome (Jeppson *et al.* 1989). However there is no report this interferon is used in case of severe combined immunodeficiency.

Here we report a case with severe combined immunodeficiency, Swiss type, who suffered from interstitial pneumonia which cleared by treatment with recombinant human interferon gamma.

CASE REPORT

A 6-month-old male infant was admitted to the hospital because of cough and dyspnea. The infant was born to a 38-year-old woman by spontaneous vaginal delivery after a full term third pregnancy. The pregnancy and delivery were uncomplicated. The birth weight was 3.6 kg. in his family history, his two elderly brothers expired due to severe combined immunodeficiency diseases at 7 months and 8 months of age respectively. His parents had no known specific illness.

At his birth, cord blood IgG was 963 mg/dl IgM was 15 mg/dl. IgA and IgE from cord blood was not detectable. IgG subclasses from the cord blood were normal (IgG₁: 732 mg/dl, IgG₂: 170 mg/dl, IgG₃: 35 mg/dl, IgG₄: 5 mg/dl). The infant's early growth and development were normal. He was vaccinated 2 times with DPT. NO other vaccinations were given. Three days before admission, a cough developed and 2 days later, dyspnea with cyanosis appeared. On the day of entry, the dyspnea became more severe. The patient was admitted to the hospital via ER. The temperature was 38.0°C, the pulse was 170/min, and the respirations were 60/min. The blood pressure was 90/50 mmHg.

On physical examination, the patient appeared acutely ill. No rash or lymphadenopathy was found. The head and neck were normal except for slightly cyanotic lips. The tonsillar tissue was not observed. Clear breath sounds were heard over both lungs. Mild substernal retraction was noted. Physical examination was otherwise negative.

The urine was normal. The hematocrit was 37.6%. The white-cell count was 20,600/mm³ with 84% neutrophils, 13% lymphocytes. The platelet count was 502,000/mm³ and the erythrocyte sedimentation rate was 5 mm per hour. The sodium

was 139 mMol, the potassium 5.0 mMol, the chloride 108 mMol, and the carbon dioxide 18 mMol per liter. The total protein was 5.3 mg/dl, the albumin 3.9 mg/dl. The serum aspartate aminotransferase (ASAT) and serum alanin aminotransferase (ALAT) were normal.

A specimen of arterial blood, drawn while the patient was breathing room air, disclosed that the PaO₂ was 47 mmHg, the PaCO₂ 37 mmHg and the pH 7.42. X-ray films of the chest showed diffuse

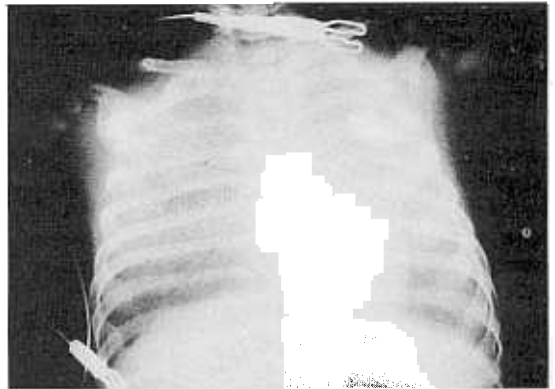


Fig. 1. A chest x-ray of this case on admission shows diffuse ground glass appearance on the both lung fields.

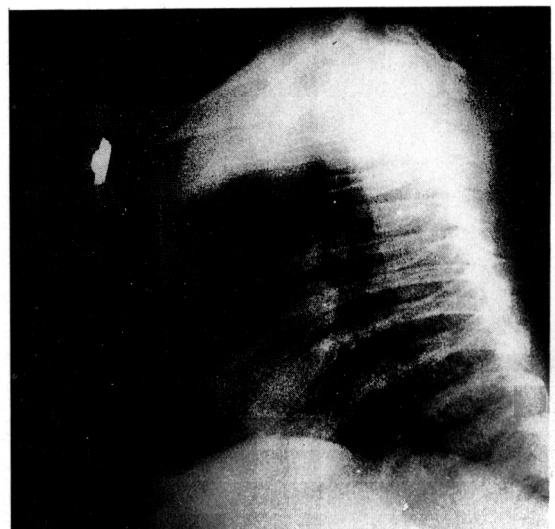


Fig. 2. A lateral view of this case on the 20th hospital day shows an absence of any shadow in the anterior mediastinum.

ground glass appearance on the both lung fields, more prominent haziness on right upper and middle lobe area with air bronchogram. Some narrowing of the mediastinum was also noted (Fig. 1). A lateral view X-ray of the anterior mediastinum which was performed on the 20th hospital day, revealed absence of the thymic shadow (Fig. 2).

After specimens of blood were obtained for culture, antibiotics (cefotaxime and amikacin) were administered by vein and oxygen was applied 10 L/min through a hood.

Serum immunoglobulins levels were markedly diminished; IgG, 21 mg/dl; IgA, 0.16 mg/dl; IgM, 65 mg/dl; and IgE < 10 IU/ml. The lymphocyte count was about 10%; B cell, 10.04%; T cell, 0.07%; CD4 T cell, 0.06%; and CD8 T cell, 0.02%. T cell function assessed by the phytohemagglutinin (PHA) and concanavalin A (Con A) were nearly absent. Multitest CMI skin test reactions including diphtheria and tetanus antigens were all negative despite previous administration of diphtheria-pertussis-tetanus vaccine. Replacement gamma globulin therapy was started intravenously.

On the seventy hospital day, the dyspnea and tachypnea worsened, and the patient became cyanotic in spite of high O₂ therapy. Because the arterial oxygen tension could not be maintained above 50 mmHg at inspired oxygen, continuous positive airway pressure (CPAP) at a pressure of 6 cmH₂O was applied through orotracheal intubation. A repeated X-ray film of chest revealed total haziness on both lung fields (Fig. 3). A therapeutic trial with IFN-gamma (Lucky Co., Ltd., Seoul, Korea) 0.05 mg/m² through subcutaneous injections once a day began on the seventh hospital day.

The patient tolerated the CPAP well. Seven days later, X-ray films of the chest showed a much improvement of haziness in comparison with a earlier examination (Fig. 4). Microscopical examination of stained specimens of sputum revealed no evidence of *P. carinii*.

On the 14th hospital day, fluorescence-activated cell sorters showed, B cell, 16.95%; T cell, 0.24%; T CD4, 0.4%; and T CD8, 0.09%. Serum immunoglobulin levels were diminished; IgG, 90 mg/dl; IgA, 1.4 mg/dl; IgM, 145 mg/dl and intravenous immunoglobulin was infused again.

Because the parents refused an open lung biopsy, another microscopical examination of stained specimen of bronchoalveolar lavage was done on the 18th hospital day, which showed no *P. carinii*. A x-ray film of the chest showed decreased interstitial marking. So ventilator weaning with extubation was

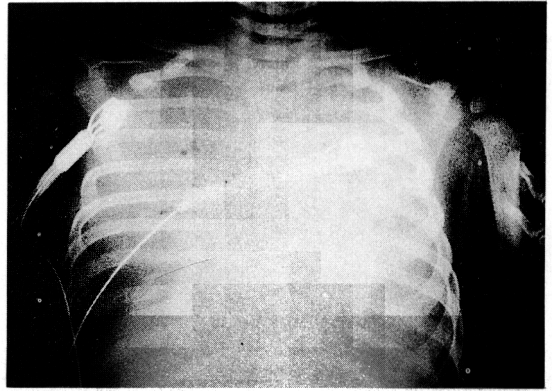


Fig. 3. A chest x-ray of this case on the 7th hospital day shows total haziness on both lung fields.

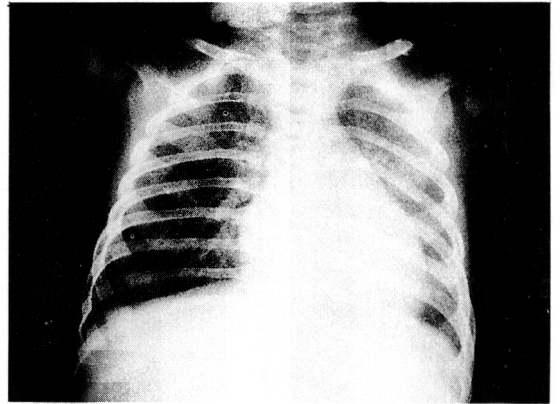


Fig. 4. A chest x-ray taken, after 7 days of treatment with recombinant human interferon-gamma, shows much improvement of haziness on both lung fields.

performed and the patient tolerated the room air without cyanosis, dyspnea, and tachypnea.

On the 24th hospital day, the serum immunoglobulin levels showed, IgG, 651 mg/dl; IgA, 0.8 mg/dl; IgM, 200 mg/dl.

The patient was comfortable and tolerated the treatment regimen well except for watery diarrhea. Stool specimen gave a negative test for *Giardia lamblia*, but a positive test for Rotavirus antigen, which converted to negative two days later. A repeated X-ray film of the chest, taken on the 44th hospital day, revealed normal findings (Fig. 5).

On the 48th hospital day, fetal thymus transplantation was performed; for the reconstitution of T cell immunity, the cultured epithelial cells of 20

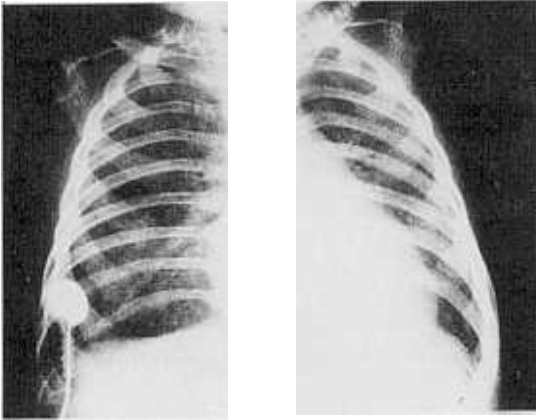


Fig. 5. A chest x-ray of this case on the 44th hospital day before discharge shows almost normal findings.

weeks old fetal thymus was injected intraperitoneally and intramuscularly. Six days after transplantation, FACS was followed, which showed some improvement; B cell, 25.64%; T cell, 2.00%; T suppressor, 0.66%; T helper, 1.01%.

The patient tolerated the treatment well and was discharged on the 80th hospital day, with plan to continue the IFN-gamma and IVIG.

DISCUSSION

We report a patient who had severe combined immunodeficiency disease with interstitial pneumonia which was cleared by treatment with recombinant human interferon gamma.

Severe combined immunodeficiency (SCID) disease is caused by a group of genetic diseases characterized by abnormal function of T and B lymphocytes, which is a result of failure of differentiation of stem cells into T cells and B cells or the thymus and bursa equivalent to develop normally (Ammann, 1991). SCID is inherited either by autosomal recessive or by X-linked recessive inheritance, but over 80 percent of the cases are of unknown genetic causes (Puck *et al.* 1990).

In this case, the patient had two elderly male siblings who expired due to immunodeficiency disorders in infancy, but the inheritance type could not be defined exactly. However we could speculate the inheritance type of this case might be X-linked recessive.

All tests of T cell immunity were abnormal in this case. The thymus was absent roentgenographically,

lymphopenia was present, T cell numbers, both T suppressor and T helper cells, were markedly depressed and the responses of isolated peripheral blood lymphocytes of phytohemagglutinin and concanavalin A were nearly absent. Delayed hypersensitivity skin tests for several organisms were all negative, although these were not absolutely indicated for diagnosis and immunoglobulin G, A, and M were markedly decreased.

The SCID patients are unusually susceptible to infection with all types of microorganisms including viruses, bacteria, fungi and protozoa, and rarely survive beyond 1 to 2 years of age if untreated. So, the major approach has been to treat patients aggressively for infection. But definitive treatment consists of transplantation of histocompatible bone marrow. In the absence of a histocompatible bone marrow donor, other forms of therapy have been used such as fetal liver (<9 weeks' gestation) and fetal thymus (<14 weeks' gestation) transplantation (Ammann, 1991).

The treatment of interstitial pneumonia of this patient was initiated with combined use of antibiotics, recombinant human interferon gamma and intravenous immunoglobulin, which resulted in marked improvement in the patient's clinical course.

Interferon gamma is a lymphokine produced by activated T lymphocytes and natural killer lymphocytes (Kasahara *et al.* 1983; Hardy *et al.* 1989). A multitude of biologic activities exerted by IFN-gamma on cells of the immune system is well documented (Ijzermans *et al.* 1990).

The greatest impact on production of interferons has been made by recombinant DNA technology, by which relatively large amounts of purified interferon are available for basic research and clinical trials (Pestka *et al.* 1987).

The actions of IFN-gamma include antiviral action against a wide variety of human viruses, both *in vitro* and *in vivo* (Wheelock, 1965). The mechanism of antiviral action is uncertain, but may be related to the intracellular production of 2, 5-oligoadenylate synthetase and eukaryotic initiating factor 2-alpha protein kinase, enzymes that lead to the degradation of viral messenger RNA translation (1981; Samuel *et al.* 1984).

The interferon also have potent modulatory effects on antigen-specific immune function, increasing preexisting class II MHC expression, inducing *de novo* expression of class II MHC on a wide variety of other cell types (Trinchieri *et al.* 1985). IFN-gamma appears to be required for the generation of cytotoxic T cells effective in killing (Gromo *et al.*

1987).

IFN-gamma has dramatic effects on monocyte and macrophage function and is probably the most important mediator of macrophage activation (Murray, 1988). IFN-gamma also enhances the capacity of these cells to migrate to sites of infection, phagocytose particles coated with IgG and complement (C3b) and produce microbial oxygen metabolites, proteases and cytokines, including IL-1 and TNF (Wilson, 1989). Treatment of NK cells with IFN-gamma enhances NK cell activity against virally infected targets (Sayers et al. 1986).

IFN-gamma can also significantly alter neutrophil function, maintaining human neutrophil phagocytic activity, reactivating oxygen metabolite production and microbicidal activity under conditions of in vitro culture (Perussia et al. 1987). IFN-gamma enhances antibody-dependent cellular cytotoxicity (ADCC) (Hardy et al. 1989), at least in part, by the increased expression of Fc receptors (Perussia et al. 1987).

IFN-gamma appears to play a critical role in host defense against intracellular pathogens including viruses such as herpes viruses and a number of nonviral agents. With experimental studies, there is evidence that IFN-gamma has a protective role in intracellular infection with bacterial pathogens, including *Rickettsia* (Li et al. 1987), *Chlamydia trachomatis* (Williams et al. 1988) and *Mycobacterium tuberculosis* (Khor et al. 1986) or intracellular (Edwards et al. 1986), as well as parasites such as *Toxoplasma* (Suzuki et al. 1988), *Leishmania* (Squires et al. 1989) and *Plasmodium* (Ferreira et al. 1986). Clinical trials are under way to evaluate the efficacy of interferon in the treatment of cancers, infections and /or immunodeficiency disorders. In patients with lepromatous leprosy (Cooper et al. 1989) and visceral leishmaniasis (Squires et al. 1990), preliminary results of IFN-gamma treatment are encouraging. Systemic administration has also shown promising in patients with chronic granulomatous disease (Gallin et al. 1990).

There are also ongoing studies of whether IFN-gamma treatment will reduce the incidence of opportunistic infections in acquired immunodeficiency syndrome patients (Lewis et al. 1990). In a recent reports some patients with Job's syndrome had significant decreases in their serum Ig E values after subcutaneous injection of IFN-gamma and in vitro incubation of the neutrophils of these patients with IFN-gamma has been reported to enhance their chemotactic responses (Jeppson et al. 1989). Future candidates for therapeutic or prophylactic uses of IFN-gamma might include those with primary

immunodeficiencies and neonates at risk for or with established serious infection (Lewis et al. 1990). it is likely that combined use of IFN-gamma, other cytokines including interleukin-2 (Weinberg et al. 1990) and other modalities such as intravenous immunoglobulin may be advantageous for certain infections in immunodeficiencies (Lewis et al. 1990).

After intravenous bolus injection, recombinant interferon gamma is cleared rapidly from the serum with a half-life of 30 minutes (Kurzrock et al. 1985). After intramuscular or subcutaneous injection, serum levels peak at 6 to 13 hours, and the serum half life is prolonged to 3.5 to 7.5 hours (Thompson et al. 1987).

The capacity of recombinant IFN-gamma to activate the blood monocyte does not however, appear to correlate with either dose or serum level (Murray et al. 1988). And, in humans, we do not as yet know how little IFN-gamma is required to successfully and persistently activate the mononuclear phagocyte in vivo (Murray et al. 1988).

It is well known from human studies that treatment with IFN-gamma may induce flu-like symptoms, including fever, shivering and gastrointestinal distress leading to nausea and loss of appetite (Kurzrock et al. 1986). But these problems are not noted in this case.

In this cases, we don't know the exact mechanisms to explain the resolution of the interstitial pneumonia. However, we can speculate that antiviral action and activated macrophages or monocytes through the recombinant human interferon gamma might have exerted its effect on the interstitial pneumonia. Though we should extend its application to more cases of severe combined immunodeficiency with interstitial pneumonia, our case suggests a new application for interferon-gamma as a potential corrective and therapeutic agent for interstitial pneumonia in congenital immunodeficiency disease. Furthermore, we could not observe any side reactions of recombinant human interferon gamma. Further experimental data is needed but in our experience, IFN-gamma was safely administered for a prolonged period of time in a child with primary immunodeficiency diseases.

REFERENCES

- Ammann AJ: *Combined antibody (B cell) and cellular (T cell) immunodeficiency disorders*. In Stites DP, Terr AI, eds. *Basic and clinical immunology*, 7th ed, Connecticut, Appleton & Lange, 1991, 341-343
- Edwards CK III, Hedegaard HB, Zlotnik A et al: *Chronic*

- infection due to *Mycobacterium intracellulare* in mice: Association with macrophage release of prostaglandin E₂ and reversal by injection of indomethacin, muramyl dipeptide, or interferon-gamma. *J Immunol* 136: 1820-1827, 1986
- Falcoff R: Some properties of virus and immune-induced human lymphocyte interferon. *J Gen Virol* 16: 251-253, 1972
- Ferreira A, Schofield L, Enea V et al: Inhibition of development of exoerythrocytic forms of malaria parasites by gamma-interferon. *Science* 232: 881-884, 1986
- Gallin JJ, Malech HL: Update on chronic granulomatous diseases of childhood: immunotherapy and potential for gene therapy. *JAMA* 263: 1533-1537, 1990
- Gromo G, Geller RL, Inverardi L, Bach FH: Signal requirements in the stepwise functional maturation of cytotoxic T lymphocytes. *Nature* 327: 424-426, 1987
- Hardy KJ, Sawada T: Human gamma interferon strongly upregulates its own gene expression in peripheral blood lymphocytes. *J Exp Med* 170: 1021-1026, 1989
- Hirschhorn R: Genetic deficiencies of adenosine deaminase and purine nucleoside phosphorylase: Overview, genetic heterogeneity and therapy. *Birth Defects* 19: 73-81, 1983
- Ijzermans JNM, Bouwman E, Bijma A, Jeekel J, Van Der Meide PH, Marquet RL: Immunomodulation by recombinant rat interferon gamma in vivo. *J Interferon Research* 10: 203-211, 1990
- Jaffe HS, Sherwin SA: *The early clinical trials of recombinant human interferon-gamma*. In Friedman RM, Morijian T, Sreevalsun T eds. *Interferons as cell growth inhibitors and antitumor factors*, New York, Alan R Liss, 1986, 509-522
- Jeppson JD, Hill HR: Recombinant human interferon gamma enhances neutrophil chemotaxis in patients with hyper-Ig E and recurrent infections. *Pediatr Res* 25: 206A, 1989
- Kasahara T, Hooks JJ, Dougherty SF, Oppenheim JJ: Interleukin 2-mediated immune interferon (IFN-gamma) production by human T cells and T cell subsets. *J Immunol* 130: 1784-1789, 1983
- Khor M, Lowrie DB, Coates AR, Mitchison DA: Recombinant interferon-gamma and chemotherapy with isoniazid and rifampicin in experimental murine tuberculosis. *Br J Exp Pathol* 67: 587-596, 1986
- Kurzrock R, Quesada JR, Rosenblum MG, Sherwin SA, Gutterman JU: Phase I study of i.v. administered recombinant gamma interferon in cancer patients. *Cancer Treat Rep* 70: 1357-1364, 1986
- Li H, Jerrels TR, Spitalny GL, Walker DH: Gamma interferon as a crucial host defense against *Rickettsia conorii* in vivo. *Infect Immun* 55: 1252-1255, 1987
- Lewis DB, Wilson CB: Gamma interferon: An immunoregulatory lymphokine with immunotherapeutic potential. *Pediatr Infect Dis J* 9: 642-651, 1990
- Murray HW: Interferon-gamma, the activated macrophage, and host defense against microbial challenge. *Ann Intern Med* 108: 595-608, 1988
- Perussia B, Kobayashi M, Rossi ME et al: Immune interferon enhances functional properties of human granulocytes: Role of Fc receptors and effect of lymphotoxin, tumor necrosis factor, and granulocyte-macrophage colony-stimulating factor. *J Immunol* 138: 765-774, 1987
- Pestka S, Langer JA: Interferons and their actions. *Ann Rev Biochem* 56: 727-777, 1987
- Puck JM, Krauss CM, Puck SM, Buckley RM, Conley ME: Prenatal test for X-linked severe combined immunodeficiency by analysis of maternal X-chromosome inactivation and linkage analysis. *N Engl J Med* 322: 1063-1066, 1990
- Reith W, Satola S, Sanchez CH et al: Congenital immunodeficiency with a regulatory defect in MHC class II gene expression lacks a specific HLA-DR promoter binding protein, RF-X. *Cell* 53: 987-1006, 1988
- Samuel CE, Duncan R, Knutsen GS, Hershey JWB: Mechanism of interferon action: increased phosphorylation of protein synthesis initiation factor eIF-2 alpha in interferon-treated, reovirus-infected mouse L929 fibroblasts in vitro and in vivo. *J Biol Chem* 259: 13451-13457, 1984
- Squires KE, Schreiber RD, McElrath MJ et al: Experimental visceral leishmaniasis: Role of endogenous IFN-gamma in host defense and tissue granulomatous response. *J Immunol* 143: 4244-4249
- Suzuki Y, Orellana MA, Schreiber RD, Remington JS: Interferon-gamma: The major mediator of resistance against *Toxoplasma gondii* Science 240: 516-518, 1988
- Thompson JA, Cox WW, Lindgren CG et al: Subcutaneous recombinant gamma interferon in cancer patients: Toxicity, pharmacokinetics, and immunomodulatory effects. *Cancer Immunol Immunother* 25: 47-53, 1987
- Weinberg K, Parkman R: Severe combined immunodeficiency due to a specific defect in the production of interleukin-2. *N Engl J Med* 322: 1718-1723, 1990
- Whelock EF: Interferon-like virus-inhibitor induced in human leukocytes by phytohemagglutinin. *Science* 149: 310-311, 1965
- Williams DM, Byrne GI, Grubbs B, et al: Role in vivo for gamma interferon in control of pneumonia caused by *Chlamydia trachomatis* in mice. *Infect Immunol* 56: 3004-3006, 1988
- Wilson CB: *Developmental immunology and role of host defenses in neonatal susceptibility*. In Remington JS, Klein JO, eds. *Infectious diseases of the fetus and newborn infant*, 3rd ed, Philadelphia, Saunders, 1989, 17-67